

Dr. Vikas Kohli

American Board Certified

(MD Peds), FAAP, FACC

Senior Consultant

Fetal, Neonatal, Pediatric Cardiology



Indraprastha Apollo Hospitals
touching lives January 2012 DELHI

To

Mr. Pradeep

Life Care

Regeneration Association

Dear Mr. Pradeep,

This is to certify that 16 Years old patient Anand Piparya S/o Devender Piparya has been evaluated by us found to have Large PDA. He needs PDA Device Closure. His expenses is likely to be 1,00,000 (One Lakh only).

This family is financially challenged hence I am requesting your kind organization to extend all possible help.

If any help can be provided for same, it would be highly appreciated.

Thanking you for all the help.



Dr. Vikas Kohli
Senior Consultant
Pediatric Cardiology & Congenital
Cardiac Surgery Unit
E-mail: vkohli_md@yahoo.com
Mobile: 9891362233



India's First Internationally Accredited Hospital

Sarita Vihar, Delhi-Mathura Road, New Delhi - 110076 (India)

Email : vkohli_md@yahoo.com

Clinic : Delhi Child Heart Center, 130 Uday Park, New Delhi - 49

Tel : 011-4532 6600 Website : childhearttreatment.com

Dr. Vikas Kohli

American Board Certified

(MD Peds), FAAP, FACC

Senior Consultant

Fetal, Neonatal, Pediatric Cardiology



Indraprastha Apollo Hospitals
DELHI
touching lives

Date: 3/1/2012

Patient Name: Anand Pipraya

Weight: 26Kg / Height: 140.8 Cm

Referring: Dr.

PCCS ID No: 5981/12

Date of Birth:

Age: 16 years / Sex: M

Echo:

- o large PDA.
L → R
gr = 30 mmHg
- o Trivial PI.
- o dilated - LA
LV.

Re: Admission for device closure.



Joint Commission
INTERNATIONAL

India's First Internationally Accredited Hospital

Sarita Vihar, Delhi-Mathura Road, New Delhi - 110076 (India)

Email : vkohli_md@yahoo.com

Clinic : Delhi Child Heart Center, 130 Uday Park, New Delhi - 49

Tel : 011-4532 6600 Website : childhearttreatment.com



Trusted name in diagnostics

Vardhman Diagnostics

Opp. Medical College, Jhansi (U.P.) • Ph.: 0510 - 2320263 - 2320804

Dr. Praveen Jain
MD (Radiodiagnosis)
Gold Medalist

Patient's Name: - Mr. Anand
Referred By: - Dr. Anil Kaushik MD.

Dated: - 24/03/2009
Age/Sex: - 12 Yrs/M

COLOR DOPPLER ECHOCARDIOGRAPHY REPORT

INTERPRETATION SUMMARY:-

PDA WITH LT TO RT. SHUNT.
DILATED LA, LV AND LVH.

CARDIAC POSITION:-

Levocardia abdominal situs.

CARDIAC SEGMENT:-

Atrial situs solitus.

Atrioventricular concordance

Ventriculoarterial concordance.

VENOUS DRAINAGE:-

Normal pulmonary venous drainage.

Normal IVC and SVC.

ATRIUM:-

LA is dilated.

Intra Atrial septum is intact. No flow seen across septum.

VENTRICLES:-

LV is dilated. Wall is thick.

IVS is intact. No flow seen across the IVS.

AORTA:-

Normal in size.

No evidence of Coactation.

PULMONARY ARTERY:-

Normal in size.

Bifurcation is well seen.

Moderate size PDA flow is seen.

MITRAL VALVE:-

Normal bicuspid valve seen.

AORTIC VALVE:-

Normal Aortic valves seen.

TRICUSPID VALVE:-

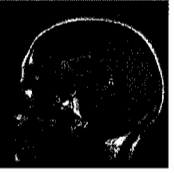
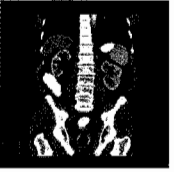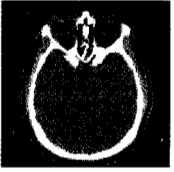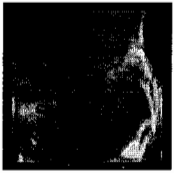Tricuspid valve is normal.

PULMONARY VALVE:-

Normal. No PS.

PERICARDIUM:-

Normal.



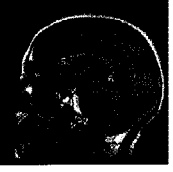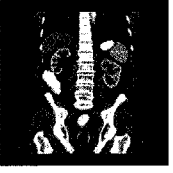
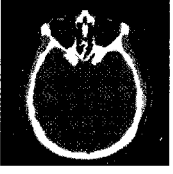

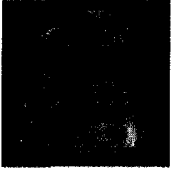
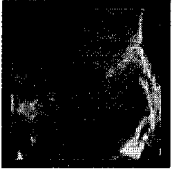Trusted name in diagnostics

Vardhman Diagnostics

Opp. Medical College, Jhansi (U.P.) • Ph.: 0510 - 2320263 - 2320804

Dr. Praveen Jain
MD (Radiodiagnosis)
Gold Medalist



M-MODE/2-D MEASUREMENTS :-

Aortic Root Diameter: - 33 mm.
Aortic valve opening: - 16 mm.
Lt. Atrial Dimension: - 40 mm.
RV Wall Thickness: - 07 mm.
RV Dimension: - 21 mm.
IVS (ED): -07mm
IVS (ES): - 12 mm.
LVID (ED): - 51 mm.
LVID (ES): - 31 mm.
LVPW (ED): - 08 mm.
LVPW (ES): - 15mm.

DOPPLER MEASUREMENTS :-

AORTIC VALVE.

Max. Velocity: - 159.86cm/sec.
PG: - 10.22mm Hg.
Mean Velocity: -
Mean PG: -

MITRAL VALVE

Max. Velocity: -127.71cm/sec.
Mean Velocity: -
Max. PG: - 6.52mm Hg.
MVA :- Normal.

PULMONARY VALVES.

Max. Velocity: - 84.84cm/sec.
Max. PG: - 2.88mm Hg.

TRICUSPID VALVE

Max. Velocity: - 88.41cm/sec.
Max. PG: - 3.13 mm Hg.

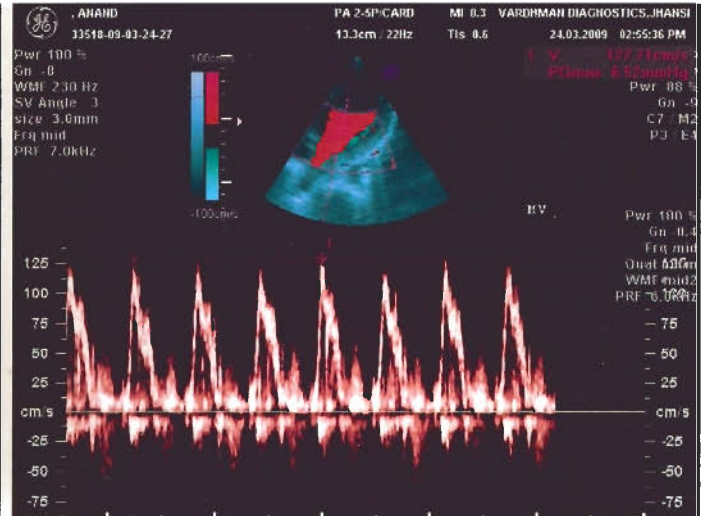
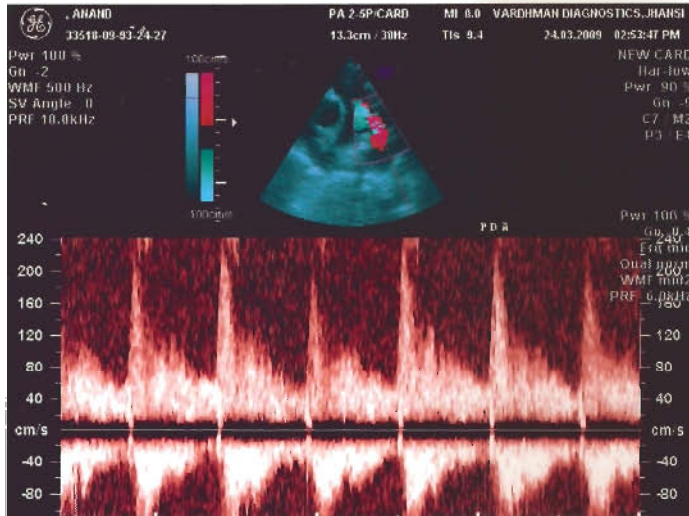
Ultrasound Report

PATIENT

Name: ANAND
ID: 33518-09-03-24-27
Birth Date:
Sex: O

EXAM

Accession #:
Exam Date: 24/03/2009
Exam Type:
Sonographer:



कार्यालय : उप जिलाधिकारी टहरौली

पत्रांक : 36311201667/उपजिलाधिकारी/टहरौली/ 2011/D-22549

दिनांक 16/09/2011

सामान्य निवास प्रमाण-पत्र

1. तहसीलदार, की जांच आख्या दिनांक **13/09/2011** के

आधार पर एतद द्वारा यह प्रमाणित किया जाता है कि

श्री/श्रीमती/कुमारी **देवेन्द्र कुमार पिपरैया**पुत्र/पुत्री/पत्नी श्री **बिहारी लाल** निवासी मकाननम्बर **टोडीफतेहपुर मु0 टोडीखास** ग्राममौहल्ला **टोडीफतेहपुर मु0 टोडीखास**तहसील **टहरौली** जनपद **झांसी**, उत्तर प्रदेश

का/की निवासी है व उसका वर्तमान पता मकान नम्बर

टोडीफतेहपुर मु0 टोडीखास ग्राम/मौहल्ला**टोडीफतेहपुर मु0 टोडीखास** तहसील**टहरौली**, जनपद **झांसी**, उत्तर प्रदेश है।

2. उपर्युक्त की पुष्टि प्रारूप-1 में आवेदक एवं सत्यापनकर्ता द्वारा उपलब्ध करायी गई सूचना तथा इससे संतुष्ट हो जाने के उपरान्त

अधोहस्ताक्षरी द्वारा उत्तर प्रदेश के इस जनपद का सामान्य निवासी विषयक प्रमाण पत्र जारी किया जा रहा है।



उप जिलाधिकारी टहरौली
झांसी (800प्र0)

नोट: उपर्युक्त प्रमाण पत्र किसी शैक्षणिक संस्था में प्रवेश अथवा किसी सेवायोजन हेतु आवेदन करने के लिए ही केवल जारी किया

गया है तथा इससे नागरिकता प्राप्त करने का कोई संबंध नहीं है। यह प्रमाण-पत्र वेबसाइट <http://bor.up.nic.in> पर इसका क्रमांक

36311201667 अंकित कर, सत्यापित किया जा सकता है।