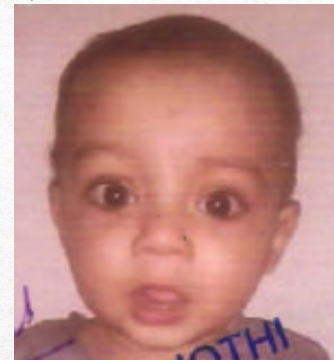

Discharge Summary

Dept. of PAEDIATRIC CARDIAC SURGERY



General Information

UHID	APD1.0011134249	Patient Identifier	DELIP314340
Ward/Bed No	1st Floor , CTVS ICU, Bed no:2157		
Name	Master. AAHIL ALI .		
Age	0Yr 9Mth 21Days	Sex	Male
Address	DALPAT PUR MURADABAD, Moradabad, Uttar Pradesh		
Primary Consultant	Dr. MUTHU JOTHI PAEDIATRIC CARDIAC SURGERY		
Admission Date	25-Oct-2020		
Discharge Date	30-Oct-2020		
Allergies	Not known		
Diagnosis	VSD with sever preliminary ^{PULMONARY} stenosis		
Surgery/Procedure	VSD closure + pulmonary valvotomy (26.10.2020)		

Present Illness

History of Present Illness

Master. AAHIL ALI came here with complaints of bluish discoloration of lips which aggravates during crying. Patient also having complaints of excessive sweating during feeding and easy fatiguability. History of increase suck rest cycle present.

No history of recurrent LRTI, syncope or failure to thrive.

No family history of CHD. No family history of SID. No history of maternal drug intake during pregnancy.

Clinical Examination

On Examination Conscious, oriented
 Afebrile
 Weight- 8 kg
 Height - 78 cm
 Pulse Rate: 126/minute
 Blood Pressure: 130/60 (85)mmHg
 Respiratory Rate: 50/minute
 SPO2-98%
 No clubbing / pedal edema / icterus / pallor / lymphadenopathy
 cyanosis +
 Chest: Bilateral clear
 Cardiovascular system: S1, S2 Normal, pansystolic murmur (+), ejection systolic murmur on pulmonary area
 Per abdomen: Soft, No tenderness, No distension
 Central nervous system: No focal neurological deficit

Course In The Hospital & Discussion

Admitted, Echo done suggestive of peri membranous VSD with severe pulmonary stenosis. planned for surgical intervention after pre-op workup. VSD closure + Valvotomy done on 26.10.2020.

Child extubated 3 hour after surgery. Inotropic support given with Adrenaline, Dobutamine and Milrinone, Adrenaline tapered off on the day of surgery. Milrinone continued for 2 days as pressure was high. ECG - Arrhythmia happened because of hypokalemia. Rhythm reverted after potassium correction. X-Ray chest- Normal. No septic foci seen.

ADVICE ON DISCHARGE

Diet As advised

Physical Activity

- Following activity to be restricted for 3 months to allow breastbone (sternum) to completely heal: Avoid rough play or activities likely to injure the chest wall: bicycling, climbing, rollerblading, skateboarding or contact sports for 6 months.
- Not to lift objects weighing more than 3- 5 kg (backpacks, younger siblings, pets, etc.) for 3 months.
- To keep arm immobilized for 24hrs after pacemaker placement.
- Avoid lifting the arm above the head. Lift the baby by holding under the arms for 4 weeks.

Discharge Syp Crocin (120) x 5 ml per orally 8th hourly for 2 days then as and when required

Medication Europed drop 0.8 ml per orally ^{twice} ~~once~~ daily 6-6.

Syp Calcimax-P x 5 ml per orally thrice daily. 6-2-10

TAB ALDOACTONE (25) x 1/3 tab x PO XOD

Other advice

- Bacterial endocarditis prophylaxis as advised.

INDRAPRASTHA APOLLO HOSPITALS
 PRESCRIPTION AUDIT
 APPROPRIATENESS REVIEW DONE
 → 6
 SIGNATURE: *Amal*
 DATE: 30.10.2020 TIME:

- Fetal echo of mother to be done at 18 weeks during the next pregnancy.
- Live vaccination after 3 months.

Follow up

Follow up with surgeon Dr. Muthu Jothi after 2 days, with prior appointment.

- Follow up with cardiologist Dr. Manisha Chakrabarti for further management.
- FOR FURTHER APPOINTMENTS OR ANY QUERY PLEASE CONTACT:
- Dr. Muthu Jyothi (Paediatric cardiac surgeon) at muthujothi@hotmail.com or 0-9560089641.
- Dr. Manisha Chakrabarti (Paediatric cardiologist) at manishamukh@hotmail.com or 0-9818982826.
- Dr. Reetesh Gupta (Paediatric cardiac intensivist) at drreetesh@rediffmail.com or 0-9818214486.

Pending Reports

Kindly bring a copy of your bill to collect the pending reports from gate no-4 (from respective labs & Gate No:7 for Radiology Reports) on week days, Monday to Saturday (8am-8pm) and Sunday (8am-2pm)

IF you have any of the following symptoms, please contact your doctor or our CMO on +911126925888 / 26825555 / 29872001/2003

1. Fever Of 101°F
2. Onset of new pain or worsening of previous pain.
3. Vomiting.
4. Breathing difficulty.
5. Altered level of consciousness.
6. Discharge from the operative wound.
7. Worsening of any symptoms.
8. Other significant concerns.

Please visit our website: www.apollohospdelhi.com

Dr. MUTHU JOTHI
PAEDIATRIC CARDIAC SURGERY
Primary Consultant


Registrar/Resident

GSTIN: 07AAACI2388N1Z4

Final Interim Bill - Bill of Supply

From Date: 25-Oct-2020


To Date: 30-Oct-2020

Name : Master AAHIL ALI

Age: 0Yr 9Mth 21Days

UHID : APD1.0011134249

Sex: Male



Father Name : DR NASIR ALI

IP Number: DELIP314340



Address : DALPAT PUR MURADABAD Moradabad Uttar Pradesh
India, Cell No:91-7037952786

Doctor Name : Dr MUTHU JOTHI
Speciality : PAEDIATRIC CARDIAC SURGERY

Bill No : INT1127326

Date : 30-Oct-2020

Time : 12:28:25

Ward Name : CTVS ICU

Bed No : 2157 (STEP DOWN)



Billing Account Type : CASH

TPA/Corporate :

Admission Date : 25-Oct-2020 2:54:00 pm

Discharge Date : 30-Oct-2020 11:01:14 am

Sl. No	Service	Amount(INR)
1	Consultation(9993)	2,250.00
2	Medical Services(9993)	10,400.00
3	Nursing and Hospitals Utilities(9993)	1,750.00
4	Nutritional and Functional Assessment Charges(9993)	2,250.00
5	OT Consumables(9993)	100.80
6	Surgical Package(9993)	231,500.00

Draft not Final

Total Interim Bill Amount Till Date

248,251.00

Deposit (9601871,9606876,9612321,9604521,9606873,9604542)(Cash:20,400.00 , Non Cash:187,

207,508.00

Payment Details:

Interim bill amount in words : Rupees : Twolakhs Forty-Eight Thousand Two Hundred Fifty-One Only

No Tax is Payable on Reverse Charge Basis

Amount Paid
Outstanding Amount

207,508.00

40,743.00

Mr. Harish Chander

Mr. Harish Chander

Cashier/Manager

Generated By

Disclaimer: This Interim Bill generated as requested by Patient for information purpose only and does not have any financial implications.
The final Bill amount may vary depending on actual consumption of services and medicines at the time of discharge.