



LIFE CARE REGENERATION ASSOCIATION

Registered Under Societies Registration Act, XXI of 1860 Regn. No. S-57088
An Institution & Rehabilitation Center for Child Development

Sponsorship form for financial Assistance for Heart Surgery & Treatment

Patient's Details

Patient Name:- Master VIHAAN (UHID No. 11194309)

Referred by: - Dr. MUTHU JOTHI (IP APOLLO HOSPITAL)

DOB: 28-12-2020 / Age: 55 days / Height: 60cm / Weight: 2.7Kg / Sex: Male

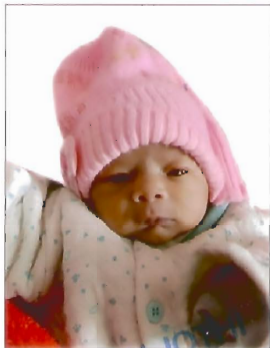Disease: - Congenital Heart Disease with Large Ventricular Septal Defect.

Treatment Advised: - VSD Closure open heart surgery.

Vihaan is 55 days old heart patient. He has got a heart disease CHD-LVSD by birth. Patient is very sick and admitted in ICU on ventilator, he is evaluated by Dr. MUTHU JOTHI and found to have this disease. He advised him for urgent VSD Closure surgery. He requires this procedure as soon as possible to save his Life. His surgery will take place at Indraprastha Apollo Hospital ND.

But Surgery and treatment is very expensive. He belongs to a poor family. His father works as a salesman in a gift shop. His annually earning is 120,000/-. There are total 4 members in the family and no any resource of the earning. Due to very poor condition of family. They are unable to afford the expenses (Rs. 3.5 to 4 lacs) of the surgery & treatment.

So their request to Life Care Regeneration Association 'LCRA' to sponsor the surgery and treatment expenses of the child.



Dr. MUTHU JOTHI
M.B.B.S., MS, M.ch (CVTS)
Senior Consultant Paediatric Cardiac Surgeon
Reg. No. 44351
Jothi

Family Details

Father Name:	Sh. HIMANSHU	Age: 31 Yrs.	Education: 12 th Passed	Occupation: Salesman
Mother Name:	Smt. VERSHA	Age: 27 Yrs.	Education: 12 th Passed	Occupation: Housewife
Family members:	4 (Four)	Number of Children:- 2(Boys)		
Number of Earning Person:	1 (One)	Total Annual Income: Rs. 120,000/- (One Lac Twenty Thousand Only)		
Resident Address:	1538/39, Aziz Ganj, Sadar Bazar, Nr. Azad Market, Delhi-110006.			

Medical Treatment Details

Registration No/IP No.:-	11194309	Bed No.	2158	Date of Surgery.	_____
Diagnosis Disease:	Congenital Heart Disease with Large Ventricular Septal Defect.				
Treatment Prescribed:	VSD Closure open heart surgery.				
Concerned Doctor and Surgeon Name:	Dr. MUTHU JOTHI (IP APOLLO Hospital)				
<u>Expenditure for which financial assistance required:-</u>					
Total Cost of Surgery and Treatment (Approx):	Rs. 500,000/- (Five Lacs Only)				
Hospital Discount:	Treatment Under Poor Patient category (IP APOLLO Hospital)				
Total Cost Surgery after discount:	Rs. 3.5 to 4 lacs (in this amount Rs. 1 lac has been arranged.)				
Total Fund Required for Surgery:-	Rs. 2.5 lacs to 3 lacs.				

Hospital Name & Address
Indraprastha Apollo Hospital
Sarita Vihar, Mathura Road, New Delhi-76

Declaration:

I declare that the information given above is true and I am not able and not in position to afford the treatment expenses of the child.

Signature of the Parents/Guardian

Life Care Regeneration Association®
Head Office:- A-223, LGF, Shivalik,
Malviya Nagar, New Delhi-110017
for LCRA seal

Authorised Signatory

Dr. MUTHU JOTHI
M.B.B.S., MS, M.ch (CVTS)
Senior Consultant Paediatric Cardiac Surgeon
Reg. No. 44351
Dr. MUTHU JOTHI (Sr. Consultant Paediatric Cardiac Surgeon)
(Department of Pediatric Cardiac Sciences, IP Apollo Hospital)

Date:- 25-02-2021

Place:- New Delhi

All Contribution to 'LCRA' are exempted from Income Tax Under Section 80G of I.T. Act, 1961 DIT(E)2008-09/L-669/1186

-: Your Support Can Be Save Someone Life :-



Accredited by
Joint Commission International



Dr. Muthu Jothi

M.B.B.S., M.S., M.Ch (CTVS)

Senior Consultant Paediatric Cardiac Surgeon

Date: 25.02.2021

TO,

Life Care Regeneration Association

Shivalik, Malviya Nagar,

New Delhi- 110017

This is to confirm that Mast. Vihaan 55 days old male (Hospital No: APDI. 0011194309) is a known case of Congenital heart disease- Large Ventricular Septal defect. Child needs emergency open heart Surgery for Closure of Ventricular Septal defect. The Cost surgery would be 3.5 - 4 lakhs Indian rupees. Parents belong to poor family and are unable to mobilise funds.

I would request you to kindly help this child for his surgical expenses.

Thanking you,
Yours Sincerely,

DR. MUTHU JOTHI

Senior Consultant

Paediatric Cardiac Surgeon

Dr. MUTHU JOTHI

M.B.B.S., MS, M.ch (CTVS)

Senior Consultant Paediatric Cardiac Surgeon

Reg. No : 44351

WORLD CLASS HEALTH CARE

Indraprastha Apollo Hospitals

Sarita Vihar, Delhi Mathura Road, New Delhi-110 076 (INDIA)

OPD Room # 1235 Gate No. 10, 2nd Floor

Tel. : +91-11-71791260 / 61 Extn. 1235

E-mail : sjm041265@gmail.com

For Appointment Contact : # 8802003509

NAME	: VIHAAN	IPD:325491
AGE/SEX	: 1MO/M	UHID: 11194309
REFERRING DR.	: DR MUTHU JOTHI	
INDICATION	: CHD	DATE: 16.02.21

Transthoracic Echo-Doppler Report

Cardiac Position:

Abdominal Situs Solitus
 Levocardia

Cardiac Segments:

Atrial Situs Solitus
 D-Loop Ventricle
 Normal related great vessels
 AV Concordance
 VA Concordance
 Two Patent AV Valve

Veins & Atria:

PFO
 Normal RA size
 Dilated LA size
 Normal Systemic Venous Drainage
 Normal Pulmonary Venous Drainage

Atrioventricular Canal:

Normal Mitral Valve
 Normal Tricuspid Valve

Conotruncus:

Normal Pulmonary Valve
 Normal Aortic Valve

Ventricles:

Dilated Left Ventricle
 Normal Right Ventricle
 Nonrestrictive perimembranous VSD with inlet extension

Great Arteries:

No evidence of coarctation of aorta
 No evidence of valvar aortic stenosis / Supravalvar aortic stenosis

Coronaries:

Normal

Keep the records carefully and bring them along during your next visit to our hospital

For enquiry & appointments contact : **011-26925801 / 26925858**

Function:

Normal LV Function

Normal RV Function

Pericardium:

Normal;

No pericardial effusion

Shunts:

Atrial shunt, L-R

Ventricular shunt, L-R

No Ductal shunt

Hemodynamics:

Normal TV velocity

Normal MV velocity

Normal PV velocity

Normal AV velocity

Mild mitral regurgitation

Trivial tricuspid regurgitation

No aortic regurgitation

PAH

Final Interpretation

PFO, L-R shunt. Nonrestrictive perimembranous VSD with inlet extension, L-R shunt. VSD gradient 14mmHg. Dilated LA, LV. Mild mitral regurgitation. Normal ventricular function. PAH.



DR. MANISHA CHAKRABARTI,

Senior Consultant,

Dept. Of Pediatric Cardiology.

Indraprastha Apollo Hospital

Keep the records carefully and bring them along during your next visit to our hospital

For enquiry & appointments contact : **011-26925801 / 26925858**



भारत सरकार
Government of India



हिमांशु
Himanshu
जन्म तिथि/DOB: 11/05/1989
पुरुष/ MALE



8721 7640 7277

VID: 9159 8626 1259 1765


मेरा आधार, मेरी पहचान



भारतीय पहचान प्राधिकरण
Unique Identification Authority of India

पता:
S/O रakesh कुमार, 1538/39 अजीज गंज, सदर बाजार,
अज़ाद मार्केट के पास, दिल्ली जी.पी.ओ. नॉर्थ दिल्ली,
दिल्ली - 110006

Address:
S/O Rakesh Kumar, 1538/39 aziz ganj,
sadar bazar, near azad market, Delhi
G.P.O., North Delhi,
Delhi - 110006



QR Code with Photograph

8721 7640 7277

VID: 9159 8626 1259 1765



www.aa.gov.in

www.aa.gov.in