




H-2008-0017
June 16, 2020 - June 15, 2023
Since June 16, 2008



Sir Ganga Ram Hospital

**DEPARTMENT OF PAEDIATRIC CARDIAC SCIENCES
DISCHARGE SUMMARY**



Dr. Raja Joshi
Dr. Neeraj Aggarwal
Dr. Reena Joshi
Dr. Mridul Agarwal
Dr. Anil Kumar

Patient Name	Miss Pawni Schrawat
Age	10 Mnths
Sex	Female
Discharge Type	DISCHARGE
Ward	5E - PCS ICU
Admitting Consultant	Consultant Paediatric Cardiac Sciences

Registration No.	2892305
Episode No.	IP01151808
Date of Admission	26-Oct-21
Date Of Discharge	29-Oct-21

DIAGNOSIS

PATENT DUCTUS ARTERIOSUS
S/P PDA LIGATION-27/10/21

CLINICAL HISTORY

History:

Child was born full term, normal vaginal delivery with no significant post natal history. At age of 9 months child had fever, cough, cold for which child was admitted in private hospital in Gurgaon. There was h/o suck rest suck cycle and feeding diaphoresis. 2D Echo was done as child had murmur it was suggestive of PDA with left to right shunt with dilated LA/LV. Child was then referred to RML Hospital for further management. Device closure was done there, but there was peridevice leak in view of which device size was upgraded but residual shunt persisted. Thereafter child was referred to SGRH for surgical ligation.

PHYSICAL EXAMINATION

Pulse: 148/min. BP: 90/40 mmHg Temperature: 37 degree C Weight: 6.65 Kg. Height: 69 cm.

General Examination:

Child was conscious, oriented, afebrile.

No pallor, icterus, clubbing, cyanosis, lymphadenopathy or oedema.

Systemic examination:

RS - Chest clear bilaterally. Air entry equal. No crepitations or wheeze.

CVS - Heart sounds normal. continuous murmur heard.

P/A - Abdomen is soft, not tender and not distended. No hepatosplenomegaly. Bowel sounds are normal.

CNS - Child was conscious and oriented. Pupils are normal sized and normally reactive to light bilaterally

CLINICAL SUMMARY

Child was admitted and after pre-operative workup, child was taken up for procedure. Child tolerated the procedure well and was shifted to PCS ICU for monitoring.


Hemodynamics: Child was hemodynamically stable. Child had high blood pressure in post operative period for which Amlodipine was started

Respiratory: Child was received extubated, on O2 by mask. Oxygen was gradually tapered and omitted as child was maintaining saturation on room air.

Infection: Antibiotics were given as per protocol. No e/o infection.



H-2008-0017
June 16, 2020 - June 15, 2023
Since June 16, 2008



Sir Ganga Ram Hospital

Gastrointestinal and nutrition: The child was started on orl feeds and tolerated well

Neurological: Child remained stable with no significant past history.

Renal: No renal issues during hospital stay

Present status: Currently patient is haemodynamically stable, maintaining saturation on room air without any distress, accepting feed orally and is being discharged with advice to follow-up.

Predischarge weight- 6.5 kg

Predischarge ECHO- no residual PDA shunt, moderate MR, No LPA branch obstruction, good biventricular function, no pericardial effusion.

DISCHARGE ADVICE

CARDIAC MEDICATIONS- (duration to be decided in opd follow up)
1. TAB AMLODIPINE (2.5MG) 1/4TH PO TWICE A DAY (1/4) 10AM - 10PM

NON CARDIAC MEDICATIONS -
1. SYRUP CALPOL (125MG/5ML) 4 ML P/O THRICE A DAY FOR 3 DAYS F/B SOS (For pain and temperature >100*
F) 8AM - 2PM - 8PM x 3 days (for)
2. SYRUP CALCIMAX P 5 ML P/O TWICE A DAY 8AM - 8PM
3. SYP BEVON 5 ML P/O ONCE A DAY 4 PM
4. DROP VIT D3 800IU/ML 1ML ONCE A DAY 2PM

DIETARY ADVISE - AS ADVISED

VACCINATION - TO BE RESUMED AFTER 6 WEEKS

FOLLOW UP

Follow up advice:


To review after 5 days in PCS OPD on 2/11/21 (F-57) in between 1PM to 3PM with prior appointment on 011-42251757. In case of emergency, please contact helpline 9650404999

1. Stitch removal on: follow up, wound clean
2. Cardiac : 2D Echo
3. Infection: Nil
4. Nutrition: As advised
5. CNS: No issues
6. Vaccination status: To be resumed after 6 weeks

- Reports of investigations done during hospital stay are provided on a separate sheet
- Pending reports can be collected from "CIC-Room no. 32, ground floor (9AM-5PM)
- Histopathology Reports, Blocks or Extra Slides can be collected from Lab 1st Floor SSRB on all working days between 9 AM - 5 PM
- Contact no. of Emergency: 011-42251098, 42251099 Contact no. of SGRH Telephone Exchange: 011-42254000, 25750000



H-2008-0017
June 16, 2020 * June 15, 2023
Since June 16, 2008



Sir Ganga Ram Hospital

- **Home Care Service:** "REACH OUT" services like Nursing Care, Sample Collection, Injections, X-rays, Physiotherapy, Dressing, Nutrition and Diet Counselling etc. are available in the comfort of your home.
Contact us at: 011-42251111 / 42253333, www.reachoutsgrh.com, reachout.sgrh@gmail.com
- **Ambulance Services / Patient Transport Service:** For Sir Ganga Ram Hospital ambulance services, kindly contact at 011-42253030 / 9717437005. PICK and DROP facility also available.

Resident Doctor

Consultant

Consultant Paediatric Cardiac Sciences
Paediatric Cardiology

Page 3 of 3



SIR GANGA RAM HOSPITAL

Department of Pediatric Cardiac Sciences



Operative Record

Name	: Pawni Sehwat	Age	: 10 months	Sex	: Female
Reg. No.	: 2892305	IP No	: 01151808	PCS ID No	: 22576/21
D.O.B	: 09.12.2020	D.O.A	: 26.10.2021	D.O.S	: 27.10.2021
Height	: 69 CM	Weight	: 6.650 Kg	Blood Group	: AB Positive

Diagnosis:

Large PDA, (Failed device on 18/10/21).

Procedure Performed

PDA ligation.

Surgeon: Dr. Raja Joshi/ Dr. Shashank Arora.

Anaesthetist: Dr. Reena Joshi

Cardiologist: Dr. Neeraj Aggarwal/ Dr. Mridul Agarwal.

Ref. Physician: Self


Comments: Child was admitted in Gurgaon in Sept for LRTI then taken to RML where murmur was found for which 2D Echo was done revealing large PDA. Re-admitted in RML for PDA device closure but procedure could not be successful. Admitted at SGRH, surgical risk explained & consent taken.

Findings:

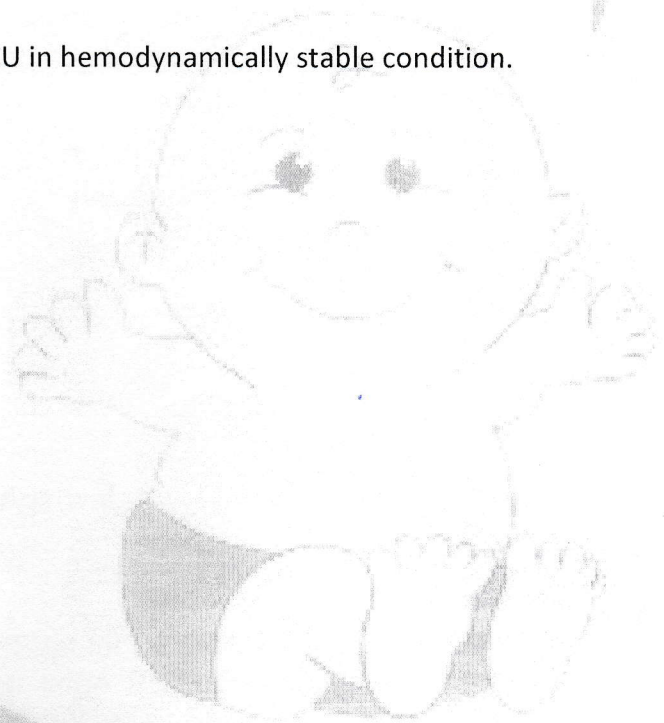
1. Normal course & origin of subclavian seen from innominate.
2. Normal left lung, large PDA.

Steps:

1. Patient was intubated with size 4.5 uncuffed orotracheal tube. Patient was positioned, prepped and draped in R lateral position.
2. L lateral muscle sparing thoracotomy in the 4th ICS.
3. Lung retracted anteriorly and inferiorly.
4. PDA was dissected and looped
5. Arch of Aorta & DTA inspected and found to be Normal in size.
6. PDA clipped.
7. Hemostasis achieved and a 16 Fr drain placed.
8. Routine thoracotomy closure.
9. All counts were correct.
10. Pt extubated in OT and shifted to PCS ICU in hemodynamically stable condition.



Dr. Raja Joshi
Senior Consultant
Pediatric Cardiac Surgeon
Dept. of Pediatric Cardiac Sciences
(Typed By: Harish)



Let Little Hearts Beat

SIR GANGA RAM HOSPITAL, Rajinder Nagar, New Delhi 110060
Provisional GSTIN : 07AABTS4366E1ZH SAC Code : 999311

BILL

Bill No.: 2021-2022/Cr/I/0014408

Name : MISS PAWNI SEHRAWAT
Age/Sex : 10 M/Female
Father's Name : NAVEEN SEHRAWAN
Address : H.NO-101, BLOCK A, ROAD NO-1,
MAHIPAL PUR EXT, DELHI-37
DELHI
Ward : WD-PCSICUW

Registration No : 2892305
Episode Number : IP01151808
Admission Date : 26/10/2021
Admission Time : 06:32PM
Discharge Date : 01/11/2021
Discharge Time : 01:06PM
No. of Days : 4
Last Room Rent. :

Unit : PAEDIATRIC CARDIAC SCIENCES

S.No.	Particulars	Gross Amt.	Amount
1	Ultrasound Charges	2580.00	2580.00
2	X Ray Department Charges	2040.00	2040.00
3	Biochemistry Laboratory Charges	2150.00	2150.00
4	Haematology Laboratory Charges	1260.00	1260.00
5	Microbiology Laboratory Charges	3210.00	3210.00
6	DOCTOR'S ANAESTHESIA CHARGES	18640.00	18640.00
7	DOCTOR'S PROCEDURE CHARGES	189224.00	189224.00
8	DOCTOR'S VISIT CHARGES.	4410.00	4410.00
9	Blood Bank Investigation Charges	530.00	530.00
10	Blood Processing Charges	6150.00	6150.00

SIR GANGA RAM HOSPITAL, Rajinder Nagar, New Delhi 110060
 Provisional GSTIN : 07AABTS4366E1ZH
 SAC Code : 999311

BILL

Bill No.: 2021-2022/Cr/I/0014408

Name : MISS PAWNI SEHRAWAT
 Age/Sex : 10 M/Female
 Father's Name : NAVEEN SEHRAWAN
 Address : H.NO-101, BLOCK A, ROAD NO-1,
 MAHIPAL PUR EXT, DELHI-37
 DELHI

Registration No : 2892305
 Episode Number : IP01151808
 Admission Date : 26/10/2021

S.No.	Particulars	Gross Amt.	Amount
11	Hospital charges	16590.00	16590.00
12	Intensive care charges	28800.00	28800.00
13	MEDICINES	8389.40	8389.40
14	Medical consumables	13183.64	13183.64
15	Non invasive laboratory charges	200.00	200.00
16	Special equipment usage charges	110.00	110.00
	Total	297467.04	297467.00

PATIENT Share
 Deposits
 Net Payable

ADMINISTRATION'S GUEST Share
 Net Payable

200000.00
 200000.00
 0.00

97467.00
 97467.00

SIR GANGA RAM HOSPITAL, Rajinder Nagar, New Delhi 110060
Provisional GSTIN : 07AABTS4366E1ZH SAC Code : 999311

BILL

Bill No.: 2021-2022/Cr/I/0014408

Name : MISS PAWNI SEHRAWAT
Age/Sex : 10 M/Female
Father's Name : NAVEEN SEHRAWAN
Address : H.NO-101, BLOCK A, ROAD NO-1,
MAHIPAL PUR EXT, DELHI-37
DELHI

Registration No : 2892305
Episode Number : IP01151808
Admission Date : 26/10/2021

Payment Details

Receipt No.	Mode	Date	Receipt Amt.	Amt Adjusted
2021/74486	Cash	26/10/2021	99500.00	99500.00
2021/74679	Cash	27/10/2021	500.00	500.00
2021/76064	Cheque	29/10/2021	5000.00	5000.00
2021/76065	Cheque	29/10/2021	1000.00	1000.00
2021/76067	Cheque	29/10/2021	87000.00	87000.00
2021/76550	Cheque	30/10/2021	7000.00	7000.00

Prepared/Received by(Arun Kumar)

For Sir Ganga Ram Hospital

Authorised Signatory

Bank Details for NEFT/RTGS

Beneficiary : Sir Ganga Ram Hospital
Bank Name : HDFC Bank Limited
Branch Address : Rajinder Nagar, New Delhi-110060
Saving Bank Account No. : 00261000043401
IFSC Code : HDFC0000026