

LIFE CARE REGENERATION ASSOCIATION

Registered Under Societies Registration Act, XXI of 1860 Regn. No. S-57088
An Institution & Rehabilitation Center for Child Development

Sponsorship form for financial Assistance for Heart Surgery & Treatment

Patient's Details



Patient Name:- Mst. TARUN

Reg. ID:- 2918936

Referred by:- Dr. NEERAJ AGGARWAL & Dr. MRIDUL AGARWAL (SGRH)

DOB:- 06-07-2016 / Age: 5.3 Yrs. / Height:- 102 cm / Weight: 21 Kgm / Sex:- Male

Disease:- (CHD) Congenital Heart Disease.

Treatment Advised:- PDA Device Closure (Patent Ductus Arteriosus).

Tarun is 5.3 yrs. old heart patient. He has got a heart disease CHD (Congenital Heart Disease) by birth. He has been evaluated by Dr. NEERAJ AGGARWAL & Dr. MRIDUL AGARWAL and found to have CHD heart disease. They advised him for PDA device closure, He needs this surgery as soon as possible for saving his Life. His surgery will take place at SIR GANGARAM Hospital ND.

But surgery and treatment is very expensive. He belongs to a poor family. His father doing some Road side vendor work (momos seller) in Agra UP. Due to very poor condition of family. They are unable to afford the whole expenses (Rs. 180,000/-) of the surgery & treatment.

So their request to Life Care Regeneration Association 'LCRA' to sponsor the surgery and treatment expenses of the child.

Family Details

Father Name:	Sh. VANTOO	Age: 33 Yrs	Education: 6 th Passed	Occupation: Road side vendor
Mother Name:	Smt. PINKI	Age: 32 Yrs	Education: NIL	Occupation: Housewife
Family members:	4 (Four)	No. of Children:-	2 Boys	
Number of Earning Person:	1 (One)	Annual Income Approx:	Rs. 90,000/- (Ninety Thousand Only)	
Permanente Address:	H.No. 10 Garhi Harray Tundla, Firozabad, UP - 283204.			
Current Address:	Vidhya Nagar, Nagla Padi, Dayal Bagh, Agra UP - 283204.			

Medical Treatment Details

Registration No:	2918936	Date of Admission/Surgery:-	_____
Diagnosis Disease:	CHD (Congenital Heart Disease)		
Treatment Prescribed:	PDA Device Closure		
Concerned Doctor and Surgeon Name:	Dr. NEERAJ AGGARWAL & Dr. MRIDUL AGARWAL (Sir Ganga Ram Hospital)		

Expenditure for which financial assistance required:-

Total Cost of Surgery and Treatment:	Rs. 250,000/-
Other discount from hospital:	Treatment Under Poor Patient Category
Total Cost of Surgery after Discount:-	Rs. 180,000/-
Total Amount of Fund Required for Surgery:	Rs. 180,000/-
(After Discount)	(One Lac Eighty Thousand Only)

Hospital Name & Address
SIR GANGA RAM Hospital
Rajinder Nagar, New Delhi-60

[Signature]



Dr. NEERAJ AGGARWAL
MD (Peds), FNI, RGHS (Ped. Card)
Consultant, Pediatric Cardiac Sciences
SIR GANGA RAM HOSPITAL
New Delhi-110074
DMC No. 25394
Doctor's Name with Department & Seal
Dr. NEERAJ AGGARWAL & Dr. MRIDUL AGARWAL Sr. Consultant
(Department of Pediatric Cardiac Sciences, Sir Ganga Ram Hospital)

Declaration:-

I declare that the information given above is true and I am not able and not in position to afford the treatment expenses of the child.

Life Care Regeneration Association®
Head Office:- A-223, LGF, Shivalik,
Malviya Nagar, New Delhi-110017

[Signature]
Signature of the Parents/Guardian

for LCRA seal
Authorised Signatory

Date:- 29-10-2021
Place:- New Delhi

All Contribution to 'LCRA' are exempted from Income Tax Under Section 80G of I.T.Act,1961 DIT(E)2008-09/L-669/1186

-: Your Support Can Be Save Someone Life :-



Department of Pediatric Cardiac Sciences
Sir Ganga Ram Hospital



DR. NEERAJ AGGARWAL

MD, (Peds), FNH, RGHHS (Pediatric Cardiology)
Consultant Pediatric Cardiologist
E-mail : drneeraj_12@yahoo.co.in
DMC Regn No. : 25394

DR. MRIDUL AGARWAL

MD (Peds), FNB (Pediatric Cardiology) National Board
Consultant Pediatric Cardiologist
E-mail : drmridul@hotmail.com
DMC Regn No. : 35769

Date: 22.10.2021

Mr. Pradeep Singh
Life Care Regeneration Association
New Delhi

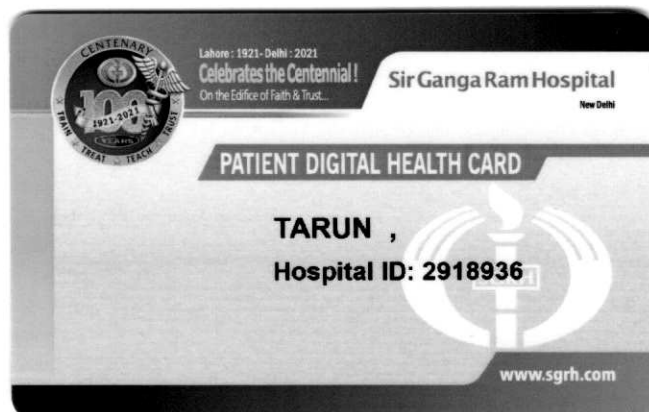Dear Mr. Pradeep

The patient Master Tarun 5 years 3 month old S/o. Mr. Vantu R/o. Vidhya Nagar, Nagla Padi, Dayal Bagh, Agra U.P -283204, has been examined by us. He has congenital heart disease, which requires cardiac procedure (PDA Device Closure). The total cost of procedure will be approximately Rs.1, 80,000/- (One Lakh Eighty Thousand Only).

This family requires financial assistance for same so kindly help them in all possible way

Regards,

Dr. Neeraj Aggarwal
MD (Peds), FNH, RGHHS (Ped. Card)
Consultant, Pediatric Cardiologist
Deptt. of Pediatric Cardiac Sciences
SIR GANGA RAM HOSPITAL
New Delhi-110060
DMC Regn No. 25394




Sir Ganga Ram Hospital Rajinder Nagar, New Delhi-110060

OPD Room No. F-57 Timings : 11.00 to 4.00 p.m. Monday to Saturday Ph. : 011-42251757 (For Appointment) 9873818788

For Peripheal OPD Contact : Mr. D. P. Singh : 9358145577, Mr. Anupam Asthana : 9910691524



H-2008-0017
June 16, 2020 - June 15, 2023
Since June 16, 2008



Sir Ganga Ram Hospital

Department of Pediatric Cardiac Sciences

NAME :TARUN

AGE : 5 YEARS 3 MONTHS

SEX : MALE

PCS ID NO. : 22867/21

DATE : 22.10.2021

REF. BY : DR.ANURAG JAIN

Pediatric Echo Report

Cardiac Position

Abdominal Situs Solitus

Levocardia

Cardiac Segments

Atrial Situs Solitus

D-loop ventricle

AV Concordance

Two Patent AV Valves

VA concordance

Normally related great Arteries

Veins & Atria

Normal Systemic Venous Drainage

Normal pulmonary Venous Drainage

Intact interatrial septum

Normal RA Size

Normal LA Size


Atrioventricular Canal

Normal Mitral valve

Normal Tricuspid valve



H-2008-0017
June 16, 2020 - June 15, 2023
Since June 16, 2008



Sir Ganga Ram Hospital

Ventricles

Normal left ventricle, LVIDd= 40mm.

Normal right ventricle

Intact Interventricular septum

Conotruncus

Normal Left ventricular outflow tract and aortic valve.

Normal Right Ventricular outflow tract and pulmonary valve

Great Arteries

Normal Ascending Aorta, arch and descending aorta

No Coarctation. 2mm PDA (Left to right shunt), Peak gradient 70mm Hg.

Confluent branch pulmonary arteries.

Function

Normal RV Function

Normal LV Function

(LVEF=60%)

Effusion


No pericardial effusion

Coronaries

Normal Coronary arteries

INTERPRETATION

- **SMALL PDA (LEFT TO RIGHT SHUNT).**
- **NO CHAMBER OVERLOAD.**
- **NO PULMONARY ARTERIAL HYPERTENSION.**


DR. NEERAJ AGGARWAL
MD (peds), FNB, RCUHS (Pediatric
Cardiology)
CONSULTANT, PEDIATRIC
CARDIOLOGIST
Sir Ganga Ram Hospital, New Delhi

Dr. MRIDUL AGARWAL
MD (peds), FNB, (Pediatric
Cardiology)
CONSULTANT, PEDIATRIC
CARDIOLOGIST
Sir Ganga Ram Hospital, New Delhi



Department of Pediatric Cardiac Sciences
Sir Ganga Ram Hospital



DR. NEERAJ AGGARWAL

MD, (Peds), FNH, RGHHS (Pediatric Cardiology)
Consultant Pediatric Cardiologist
E-mail : drneeraj_12@yahoo.co.in
DMC Regn No. : 25394

DR. MRIDUL AGARWAL

MD (Peds), FNB (Pediatric Cardiology) National Board
Consultant Pediatric Cardiologist
E-mail : drmridul@hotmail.com
DMC Regn No. : 35769

13/10/21

Mst. Tarun

8y / Male

wt. - 20kg

Normal

Out Murmur

Ear

Sai Clinic

Swan POA (2-2)

Plan

POA device check

EZ



भारत सरकार
GOVERNMENT OF INDIA



पिंकी
Pinki
जन्म तिथि/ DOB: 01/01/1989
महिला / FEMALE



4346 4945 8452

आधार-आम आदमी का अधिकार



भारत सरकार
Government of India



वन्दू
Vantoo
जन्म तिथि/DOB: 01/01/1988
पुरुष/ MALE



2684 1461 4980

मेरा आधार, मेरी पहचान



भारतीय विशिष्ट पहचान प्राधिकरण
UNIQUE IDENTIFICATION AUTHORITY OF INDIA

पता:
अर्धागिनी: बन्तू कुमार, 10,
गद्दी हरगय, टूंडला **,
फिरोजाबाद,
उत्तर प्रदेश - 283204

Address:
W/O. Bantu Kumar, 10, gadhi harray,
Tundla **, Firozabad,
Uttar Pradesh - 283204

4346 4945 8452


Aadhaar-Aam Admi ka Adhikar



भारतीय विशिष्ट पहचान प्राधिकरण
Unique Identification Authority of India

पता:
S/O बहादुर सिंह, गद्दी हरगय, टूंडला **, फिरोजाबाद,
उत्तर प्रदेश - 283204

Address:
S/O Bahadur Singh, gdhi harraya, Tundla **,
Firozabad,
Uttar Pradesh - 283204



2684 1461 4980

1947

Help @ uidai.gov.in

www.uidai.gov.in