



LIFE CARE REGENERATION ASSOCIATION

Registered Under Societies Registration Act. XXI of 1860 Regn. No. S-57088
An Institution & Rehabilitation Center for Child Development

Sponsorship form for financial Assistance for Heart Surgery & Treatment

Patient's Details

Patient Name:- KIRAN KUMARI **Reg. ID:- 2945878 / PCS ID No. 23179/21**
Referred by:- Dr. NEERAJ AGGARWAL & Dr. MRIDUL AGARWAL (SGRH)
DOB: - 10-08-2015 / Age: 6.4yrs. / Height:- 110 cm / Weight: 20.1 Kgm / Sex:- Female
Disease: - (CHD) Congenital Heart Disease.
Treatment Advised: - PDA Device Closure (Patent Ductus Arteriosus).
Kiran is 6.4yrs old heart patient. She has got a heart disease CHD by birth. She has been evaluated by Dr. NEERAJ AGGARWAL & Dr. MRIDUL AGARWAL and found to have CHD heart disease. They advised her for PDA device closure, she needs this procedure as soon as possible because she has problem in feeding. Her surgery will take place at SIR GANGARAM Hospital New Delhi.
But Surgery and treatment is very expensive. She belongs to a poor family. Her father works as a road side tea vendor (tea stall). Due to very poor condition of family. They are unable to afford the whole expenses (Rs. 180,000/-) of the surgery & treatment.
So their request to Life Care Regeneration Association 'LCRA' to sponsor the surgery and treatment expanses of the child.



Baby
KIRAN

Family Details

Father Name: Sh. PARMESH KR BOSAK **Age:** 31 Yrs **Education:** NIL **Occupation:** Tea vendor (tea stall)
Mother Name: Smt. MAMTA DEVI **Age:** 28 Yrs **Education:** 5th pass **Occupation:** Housewife
Family members: 5 (Five) **No. of Children:-** 3 (three)
Number of Earning Person: 1 (One) **Approx Annual Income:** Rs. 110,000/- (One Lac Ten Thousand Only)
Resident Address: Village Marwa Panchayat Bangama, Thana-Baisi, Word No-11, Marua, Punia, Bihar-854317.

Medical Treatment Details

Registration No: 2945878 **PCS Id.** 23179/21 **Date of Admission/Surgery:-** _____
Diagnosis Disease: CHD (Congenital Heart Disease)
Treatment Prescribed: PDA Device Closure
Concerned Doctor and Surgeon Name: Dr. NEERAJ AGGARWAL & Dr MRIDUL AGARWAL (Sir Ganga Ram Hospital)

Expenditure for which financial assistance required:-

Total Cost of Surgery and Treatment: Rs. 250,000/-
Other discount from hospital: Treatment Under Poor Patient Category
Total Amount of Fund Required for Surgery: **Rs. 180,000/-**
(After Discount) (One Lac Eighty Only)

Hospital Name & Address
SIR GANGA RAM Hospital
Rajinder Nagar, New Delhi-60



Dr. NEERAJ AGGARWAL
MD (Peds), FNB, RGDMS (Ped. Card)
Consultant, Pediatric Cardiologist
Deptt. of Pediatric Cardiac Sciences
SIR GANGA RAM HOSPITAL
New Delhi-110074
DMC No. Doctor's Name with Department & Seal
Dr. NEERAJ AGGARWAL & Dr. MRIDUL AGARWAL Sr. Consultant
(Department of Pediatric Cardiac Sciences, Sir Ganga Ram Hospital)

Declaration:-

I declare that the information given above is true and I am not able and not in position to afford the treatment expenses of the child.
Life Care Regeneration Association®
Head Office:- A-223, LGF, Shivalik, Malviya Nagar, New Delhi-110017

Signature of the Parents/Guardian

for LCRA seal
Authorised Signatory

Date:- 05- 01- 2022
Place:- New Delhi

All Contribution to 'LCRA' are exempted from Income Tax Under Section 80G of I.T.Act,1961 DIT(E)2008-09/L-669/1186

-: Your Support Can Be Save Someone Life :-



Department of Pediatric Cardiac Sciences
Sir Ganga Ram Hospital



DR. NEERAJ AGGARWAL

MD, (Peds), FNH, RGHHS (Pediatric Cardiology)
Consultant Pediatric Cardiologist
E-mail : drneeraj_12@yahoo.co.in
DMC Regn No. : 25394

DR. MRIDUL AGARWAL

MD (Peds), FNB (Pediatric Cardiology) National Board
Consultant Pediatric Cardiologist
E-mail : drmridul@hotmail.com
DMC Regn No. : 35769

Date: 21.12.2021

To
Mr. Pradeep Singh
Life Care Regeneration Association
New Delhi

Dear Mr. Pradeep

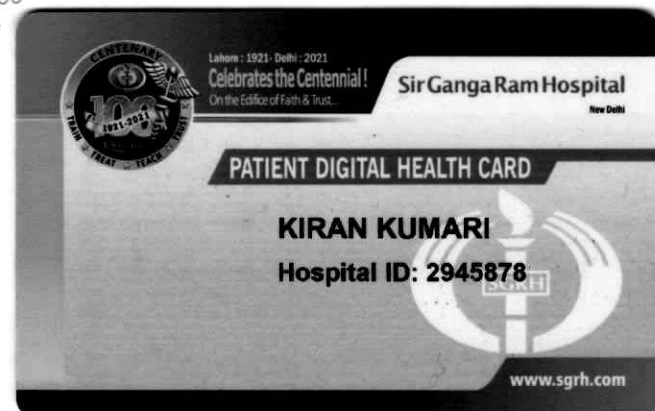The patient Baby Kiran Kumari 6 years 4 months old D/o. Mrs. Mamta Devi, R/o. Village – Marua Panchayat Bangama, Thana-Baisi Word No 11, Marua, Purnia, Marwa, Bihar - 854317, has been examined by me. She has congenital heart disease, which requires cardiac procedure (PDA Device Closure). The total cost of procedure will be approximately Rs. 1, 80,000/- (One Lakh Eighty Thousand Only).

This family requires financial assistance for same so kindly help them in all possible way

Regards,

Neeraj
Dr. Neeraj Aggarwal
Consultant Pediatric Cardiologist
Dept. of Pediatric Cardiac Sciences
Sir Ganga Ram Hospital

Dr. NEERAJ AGGARWAL
MD (Peds), FNH, RGHHS (Ped. Card)
Consultant, Pediatric Cardiologist
Deptt. of Pediatric Cardiac Sciences
SIR GANGA RAM HOSPITAL
New Delhi-110060
DMC No. 25394



Sir Ganga Ram Hospital Rajinder Nagar, New Delhi-110060

OPD Room No. F-57 Timings : 11.00 to 4.00 p.m. Monday to Saturday Ph. : 011-42251757 (For Appointment) 9873818788



Department of Pediatric Cardiac Sciences
Sir Ganga Ram Hospital



DR. NEERAJ AGGARWAL

MD, (Peds), FNH, RGHHS (Pediatric Cardiology)
Consultant Pediatric Cardiologist
E-mail : drneeraj_12@yahoo.co.in
DMC Regn No. : 25394

DR. MRIDUL AGARWAL

MD (Peds), FNB (Pediatric Cardiology) National Board
Consultant Pediatric Cardiologist
E-mail : drmridul@hotmail.com
DMC Regn No. : 35769

21/12/21
DOB: 10/8/15
Sex: female

Kiran Kumari

PCSD: 23/79/21
wt 20.1 kg

Recurrent cold/cough
chest infections

Ech.

4 mm PDA (L-R) PF 75 - 178

Dilated LA/LV


No PPH.

Plan

PDA device closure



H-2008-0017
June 16, 2020 - June 15, 2023
Since June 16, 2008



Sir Ganga Ram Hospital

Department of Pediatric Cardiac Sciences

NAME : KIRAN KUMARI
SEX : FEMALE
DATE : 21.12.2021

DOB : 10.08.2015
PCS ID NO. : 23179/21
REF. BY : DR. DEEPAK

Pediatric Echo Report

Cardiac Position

Abdominal Situs Solitus
Levocardia

Cardiac Segments

Atrial Situs Solitus
D-loop ventricle
AV Concordance
Two Patent AV Valves
VA concordance
Normally related great Arteries

Veins & Atria


Normal Systemic Venous Drainage
Normal pulmonary Venous Drainage
Intact interatrial septum
Normal RA Size
LA Size. LA/ AO 1.6.

Atrioventricular Canal

Normal Mitral valve
Normal Tricuspid valve



H-2008-0017
June 16, 2020 - June 15, 2023
Since June 16, 2008



Sir Ganga Ram Hospital

Ventricles

Normal left ventricle

Normal right ventricle

Intact Interventricular septum

Conotruncus

Normal Left ventricular outflow tract and aortic valve.

Normal Right Ventricular outflow tract and pulmonary valve

Great Arteries

Normal Ascending Aorta, arch and descending aorta

3.5mm PDA left to right shunt, Peak gradient 75mm Hg.

Confluent branch pulmonary arteries.

Function

Normal RV Function

Normal LV Function

(LVEF=60%)

Effusion

No pericardial effusion


Coronaries

Normal Coronary arteries

INTERPRETATION

- **MODERATE SIZE PDA.**
- **DILATED LA.**
- **GOOD FUNCTION.**

DR. NEERAJ AGGARWAL
MD (peds), FNH, RGUHS (Pediatric
Cardiology)
CONSULTANT, PEDIATRIC
CARDIOLOGIST
Sir Ganga Ram Hospital, New Delhi


Dr. MRIDUL AGARWAL
MD (peds), FNB, (Pediatric
Cardiology)
CONSULTANT, PEDIATRIC
CARDIOLOGIST
Sir Ganga Ram Hospital, New Delhi

